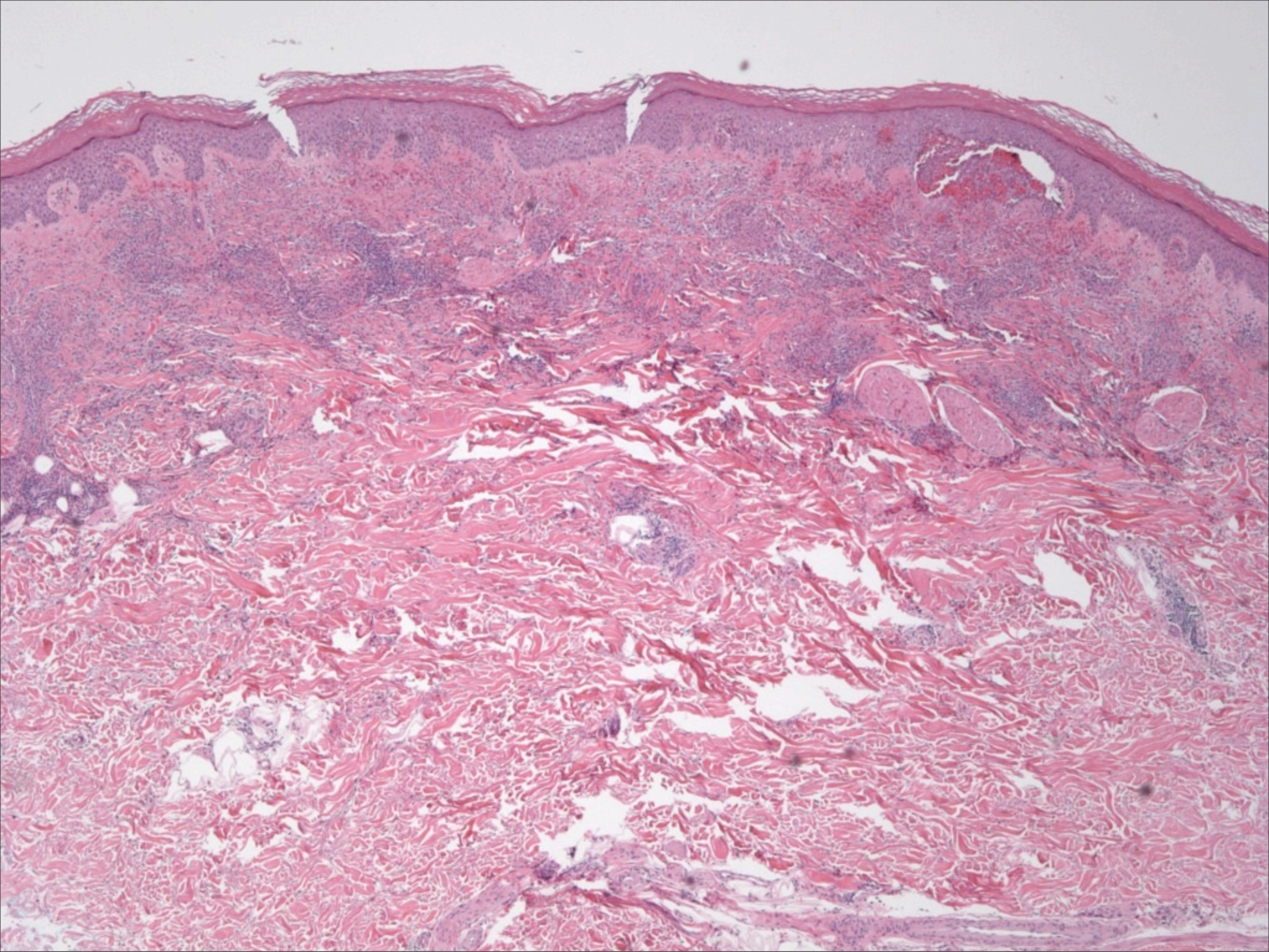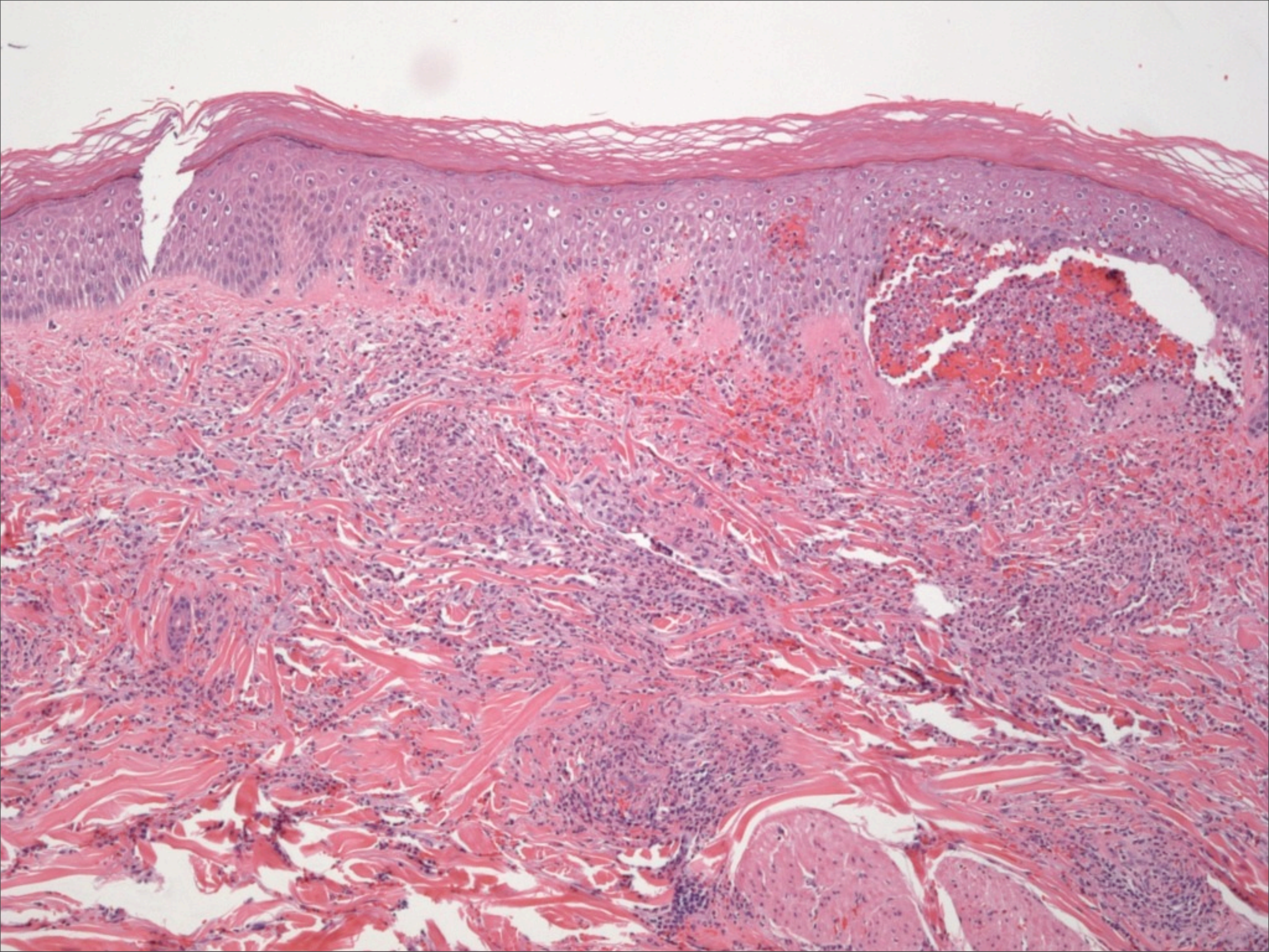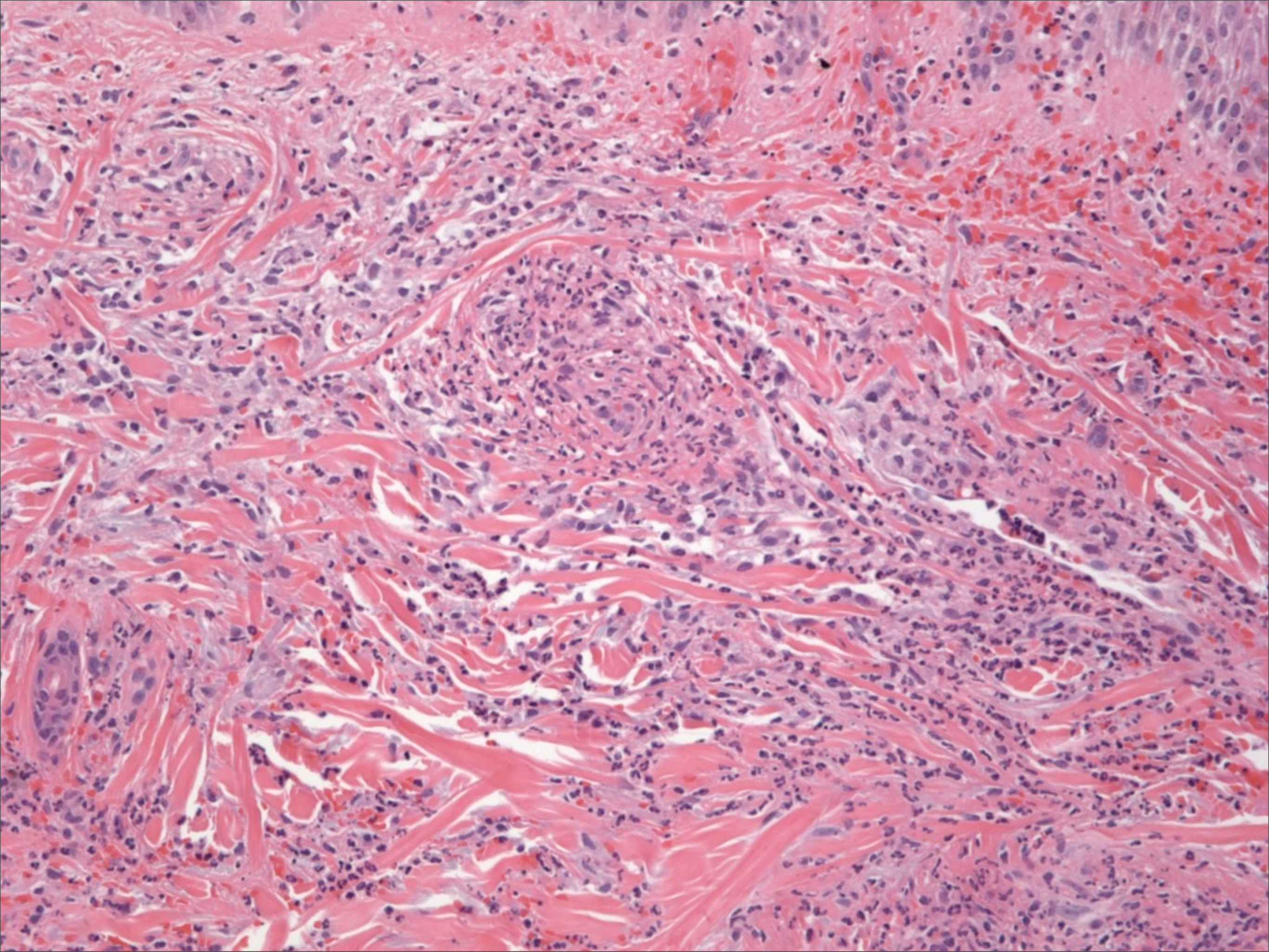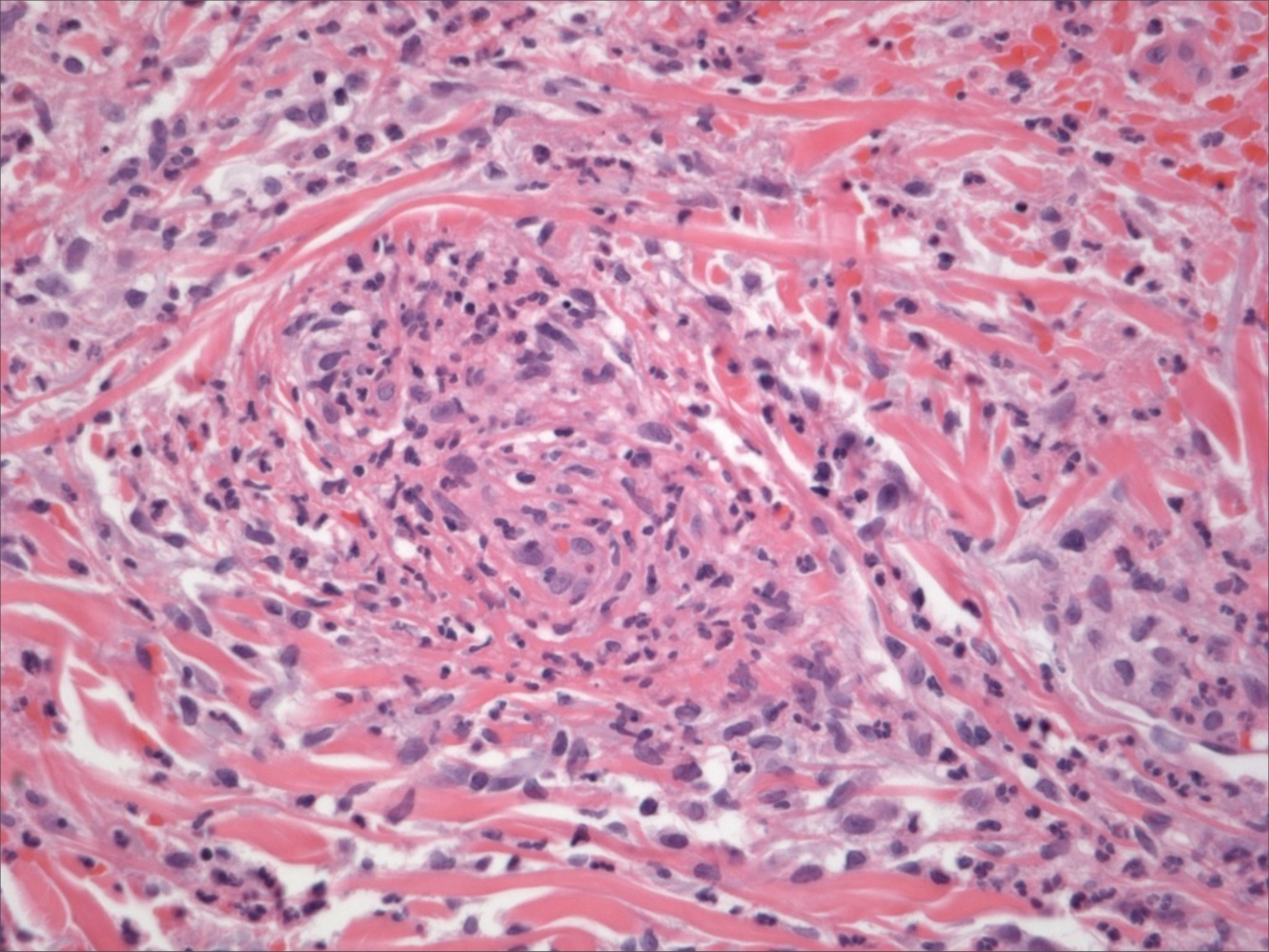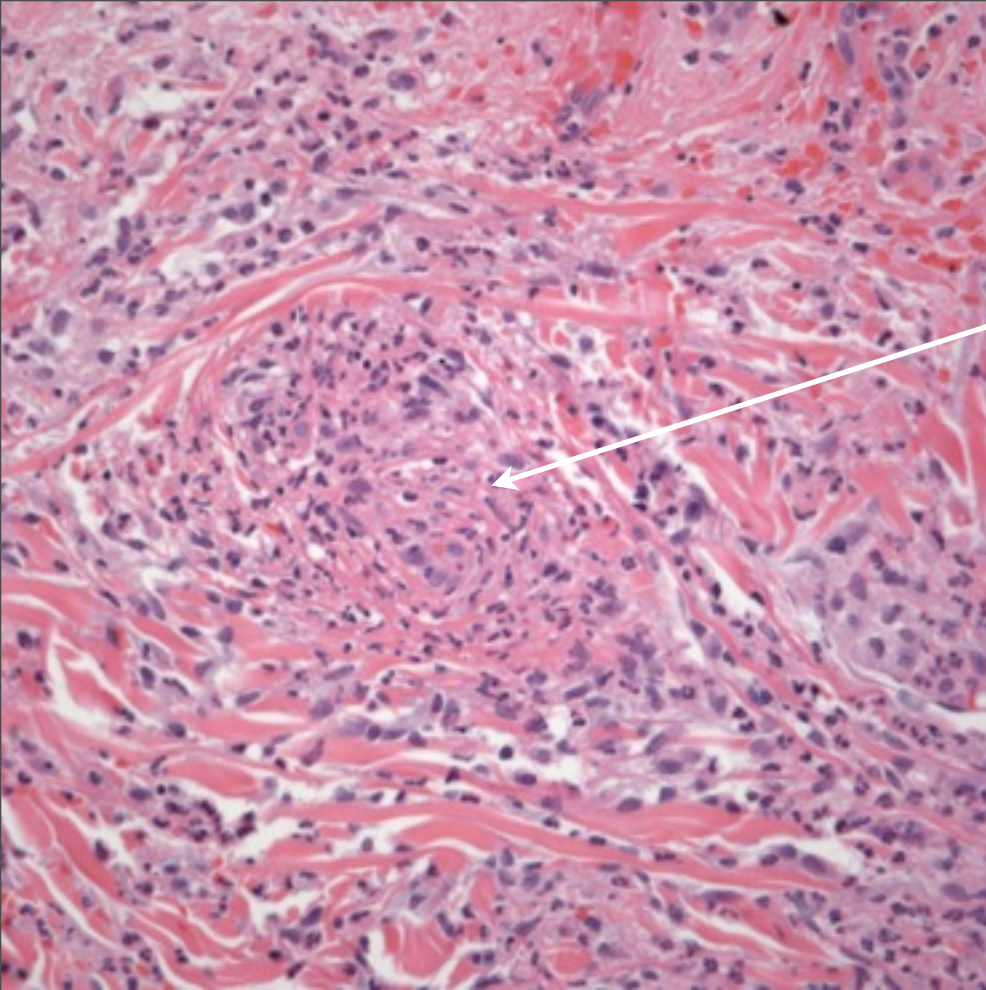


Leukocytoclastic vasculitis



Must have fibrinoid necrosis
of the vessels

Nuclear dust or hemorrhage
insufficient for dx

May occasionally show
bullous changes

